



EFFECT OF CERVICAL DISC PROTHESIS PLACEMENT IN THE SAGITTAL PLANE ON THE KINEMATICS OF IMPLANTED SEGMENTS

As presented at the Global Symposium on Motion Preservation Technology • 7th Annual Meeting • 1– 4 May, 2007 Berlin/Germany

Tzermiadianos M.N.¹, Voronov L.I.¹, Renner S.M.², Carandang G.², Havey R.M.², Patwardhan A.G.¹

¹ Loyola University Chicago, Orthopaedic Surgery and Rehabilitation, Maywood, USA

² Edward Hines, Jr. VA Hospital, Hines, USA

Summary

- This study suggests that placement of this compressible six-degree-of-freedom artificial disc as far posterior as possible is not required.
- ROM and COR of the implanted segment were not adversely affected by placement variability in the sagittal plane, although the COR showed a trend to shift posteriorly in the posterior placement.
- Avoiding far posterior placement, apart from being safer, may better replicate segmental COR kinematics for C5-C6.
- This study suggests insensitivity of the tested disc prosthesis to placement in the sagittal plane.

EFFECT OF CERVICAL DISC PROTHESIS PLACEMENT IN THE SAGITTAL PLANE ON THE KINEMATICS OF IMPLANTED SEGMENTS

As presented at the Global Symposium on Motion Preservation Technology • 7th Annual Meeting • 1– 4 May, 2007 Berlin/Germany

Purpose

In cervical total disc replacement (TDR) positioning the midline of the prosthesis slightly posterior to the midpoint of the intervertebral space allows better matching of the prosthesis center of rotation (COR) to the center of rotation of the intact segment. However, implantation in a more anterior position is not uncommon in clinical practice. This study examines the effects of implant placement in the sagittal plane using a compressible six-degree-of-freedom cervical disc prosthesis (Spinal Kinetics, Sunnyvale, CA), composed of fiber matrix and polymer core.

Methods

Six human cervical spines (C3-C7, age: 50.8±4.0 years) were tested in flexion-extension, lateral bending and axial rotation (±1.5 Nm): (i) intact (ii) after implantation of a prosthesis at C5-C6 in an anterior position, and (iii) after advancing the prosthesis to a more posterior position. Flexion-extension was tested under 150N follower preload. Range of motion (ROM) was calculated in all tested directions. Additionally, the COR in the sagittal plane was assessed by computerized fluoroscopy image analysis (Medical Metrics, Houston, TX).

Results

In the anterior placement the center of prosthesis was 0.40±0.50 mm anterior to the midline of the segment, while in the posterior placement it was 1.6±0.3 mm posterior to the midline of the segment. The difference between the two positions was significant (p<0.05). After implantation, C5-C6 flexion-extension ROM increased compared to intact from 14.6±1.7 to 16.9±3.3 degrees with the device in the anterior position (p=0.05) and to 17.4±3.6 degrees when in the posterior position (p=0.05). Total lateral bending decreased from 7.4±2.2 to 4.6±1.1 degrees in the anterior placement (p=0.003), and to 4.2±0.8 degrees in the posterior placement (p=0.004). Total axial rotation decreased from 9.8±1.6 to 8.3±1.3 degrees in the anterior placement (p=0.002) and to 8.1±1.8 in the posterior placement (p=0.028). There was no significant difference in the ROM in all tested directions between the anterior and posterior placements (p>0.05).

The COR in the intact C5-C6 segment was 2.4±0.8 mm posterior to the midpoint of the upper endplate of C6 vertebra and just below the endplate within C6 vertebral body. As compared to intact, the anterior placement did not significantly affect the COR (p=0.4), while the posterior placement tended to shift the COR 0.9±0.4 mm posteriorly (p=0.08). The difference in the COR location between anterior and posterior placements was significant (p=0.015). After TDR implantation, the vertical location of the COR moved 2.6±0.8 mm upwards (p<0.05) and located within the prosthesis.

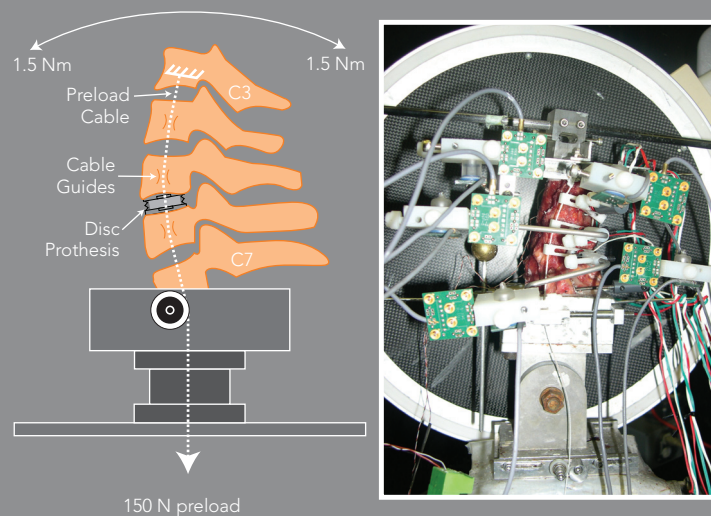
Conclusions

This study suggests that placement of this compressible six-degree-of-freedom artificial disc as far posterior as possible is not required. ROM and COR of the implanted segment were not adversely affected by placement variability in the sagittal plane, although the COR showed a trend to shift posteriorly in the posterior placement. Avoiding far posterior placement, apart from being safer, may better replicate segmental COR kinematics for C5-C6. The applicability of these findings to other cervical segments or other types of disc prostheses should be the subject of further research. With respect to the COR, this study suggests the tested disc prosthesis is insensitive to placement in the sagittal plane.

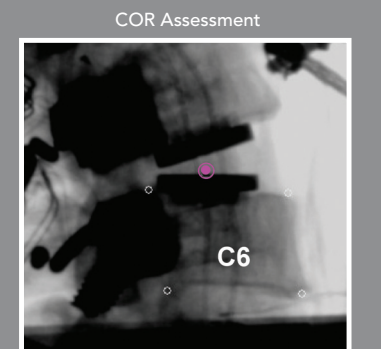
Tzermiadianos M.N.¹, Voronov L.I.¹, Renner S.M.², Carandang G.², Havey R.M.², Patwardhan A.G.¹

¹ Loyola University Chicago, Orthopaedic Surgery and Rehabilitation, Maywood, USA

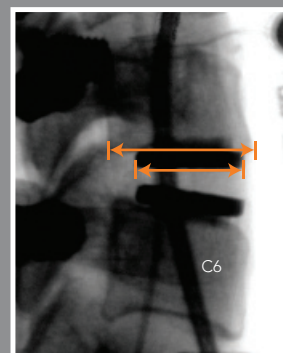
² Edward Hines, Jr. VA Hospital, Hines, USA



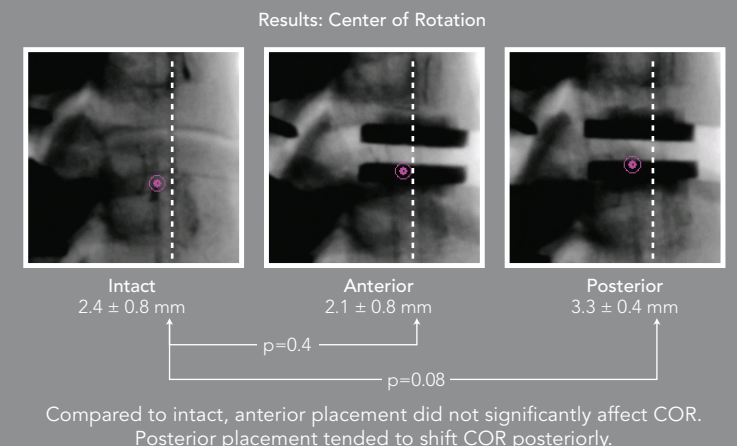
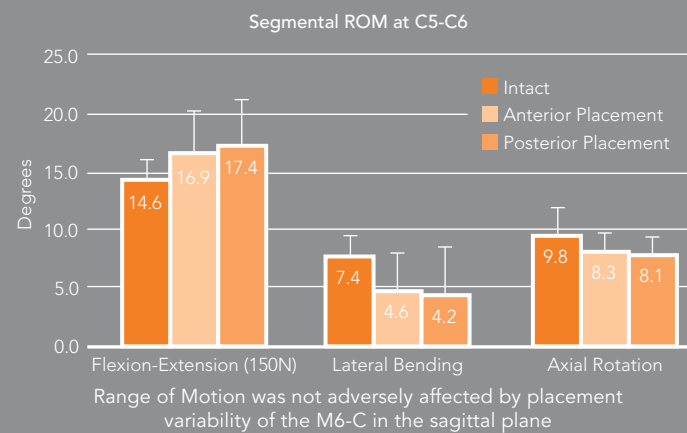
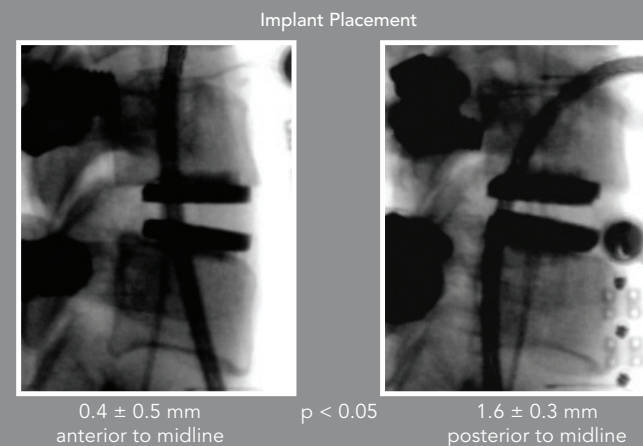
Schematic of a cervical spine mounted in the biomechanical test set-up (left). A 150N follower load is applied through the center of rotation of each segment via the Preload Cable. A moment of ± 1.5 Nm is applied and the resulting ROM is measured with the attached sensors (right).



COR in sagittal plane was assessed by computerized fluoroscopy image analysis.



Implant Placement - Relative to Midline
Center of prosthesis was measured in relation to midpoint of lower endplate of C5



Compared to intact, anterior placement did not significantly affect COR. Posterior placement tended to shift COR posteriorly.